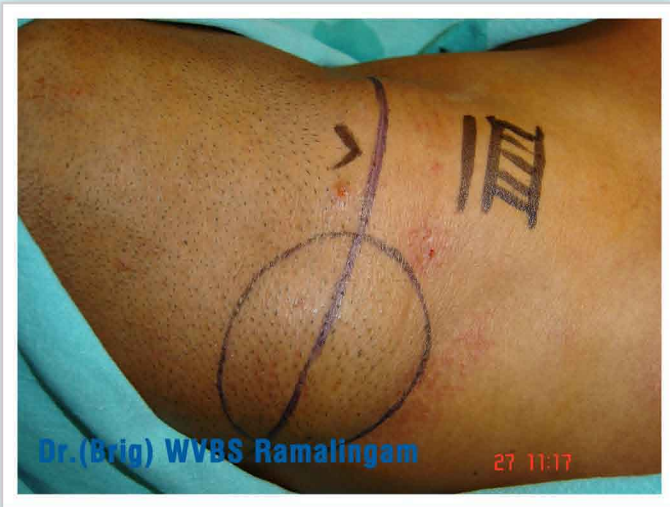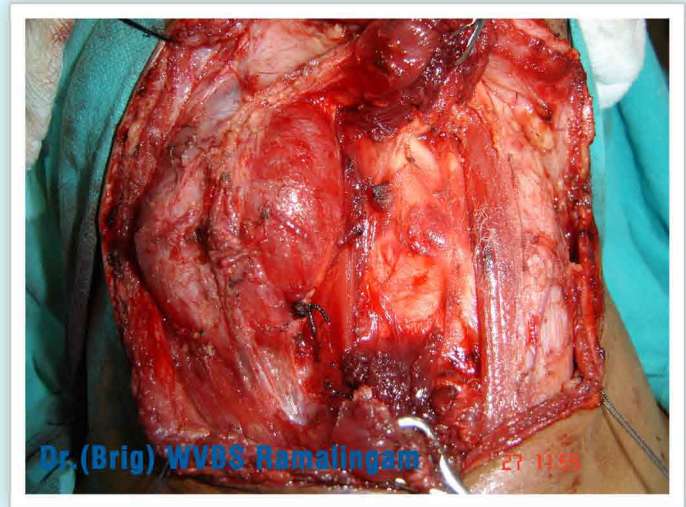




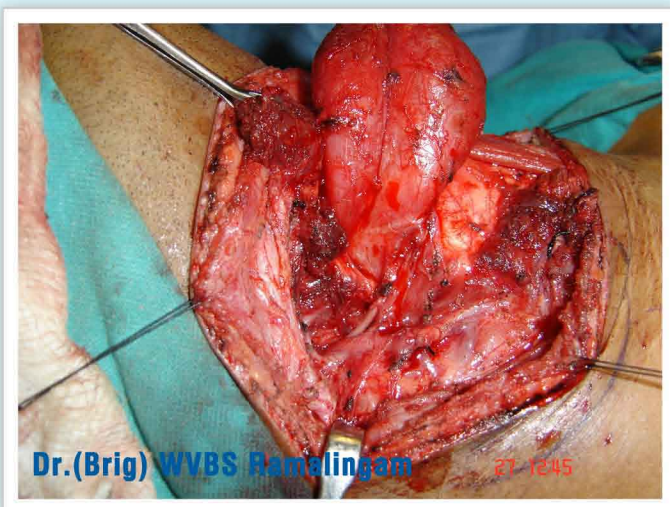### LARYNGOCOELE



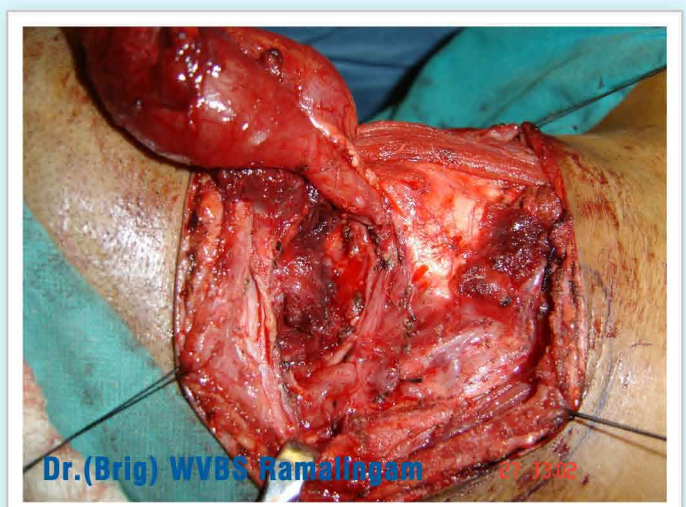Shows tumor outline and incision line



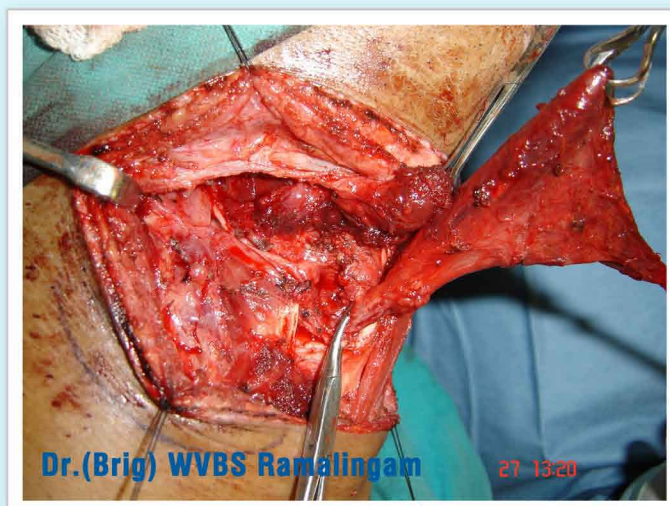
Laryngocele exposed



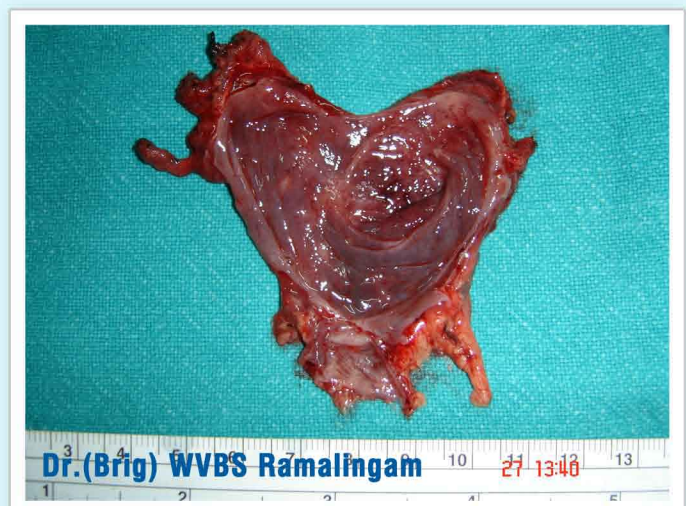
Laryngocele being dissected out



Tumor being dissected out and ligated



Tumor being dissected out and ligated



Cut opened specimen of Laryngocele