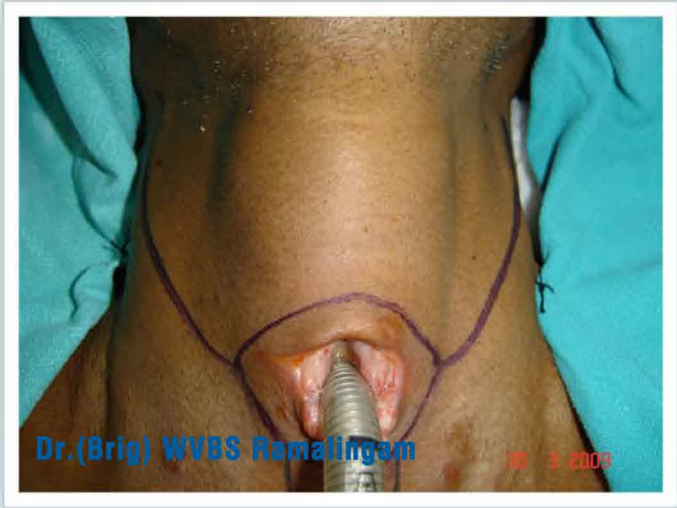




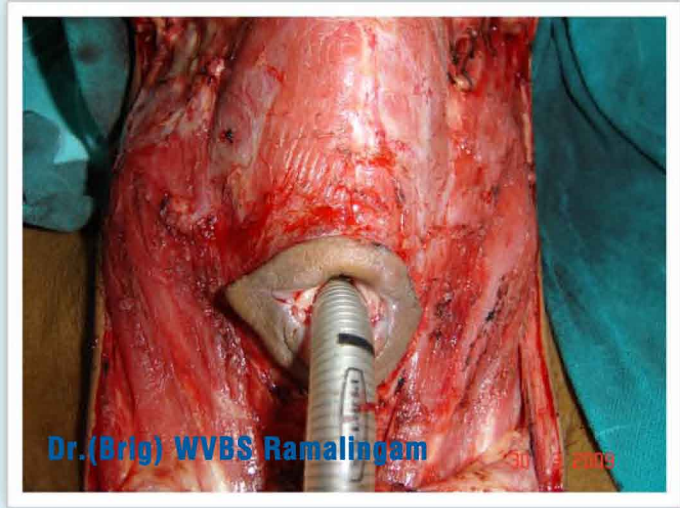
LARYNGEAL/ HYPO PHARYNGEAL OR THROAT CANCERS



Dr.(Brig) WVBS Ramalingam

30 3 2009

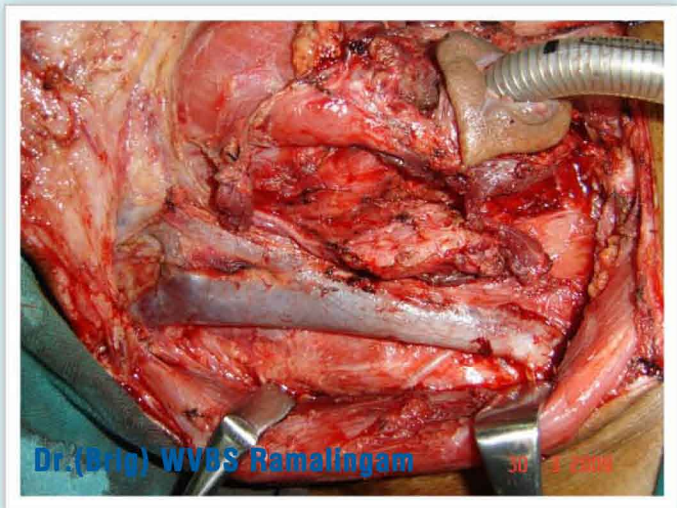
Laryngectomy in advanced cancer



Dr.(Brig) WVBS Ramalingam

30 3 2009

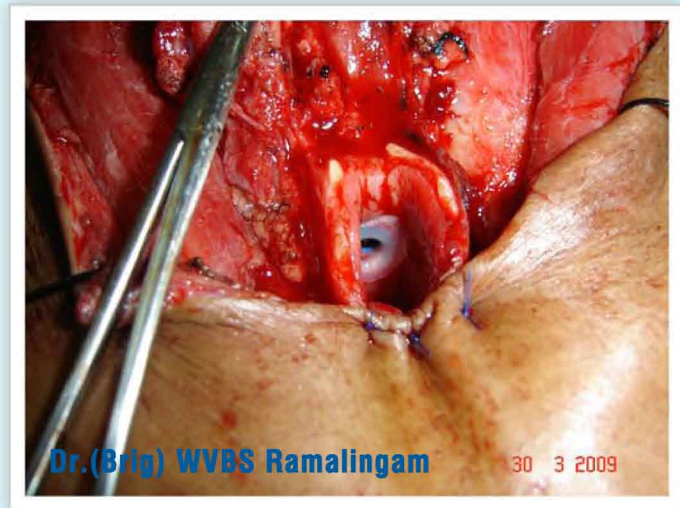Laryngectomy in advanced cancer



Dr.(Brig) WVBS Ramalingam

30 3 2009

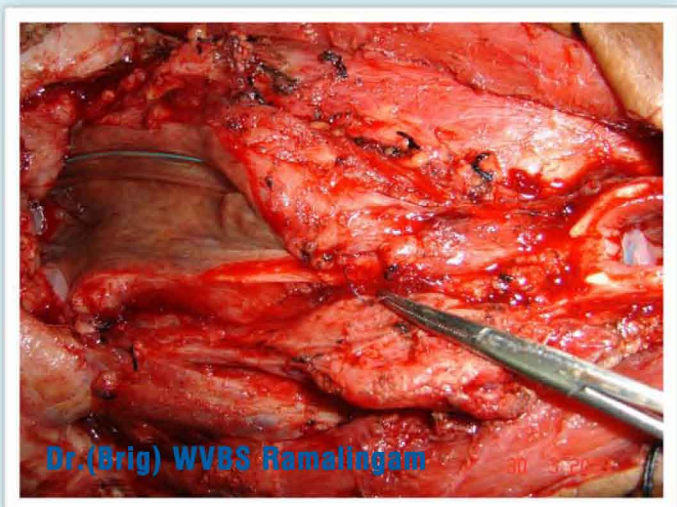
Removal of lymph nodes



Dr.(Brig) WVBS Ramalingam

30 3 2009

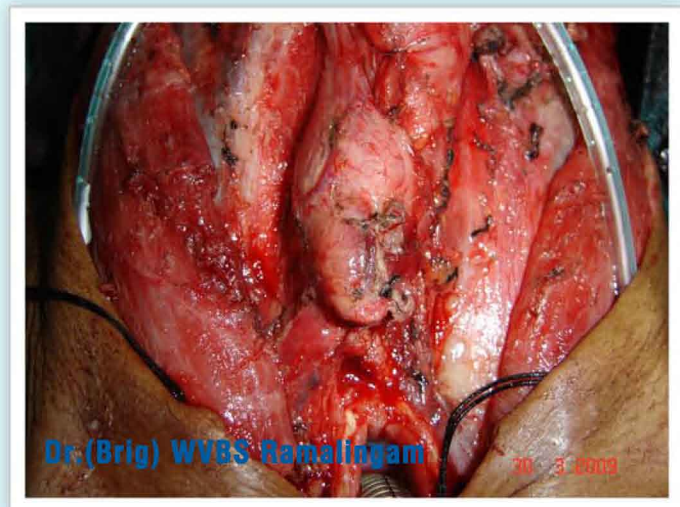
After removal of Larynx Speaking valve inserted



Dr.(Brig) WVBS Ramalingam

30 3 2009

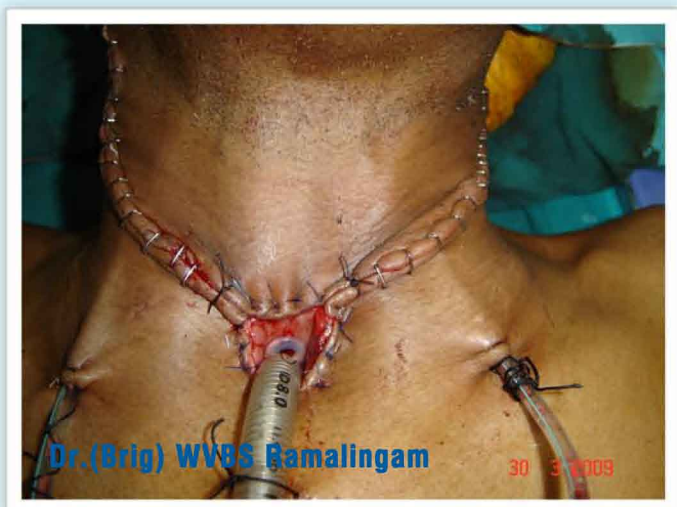Closure of wound after creating neo pharynx or food pipe



Dr.(Brig) WVBS Ramalingam

30 3 2009

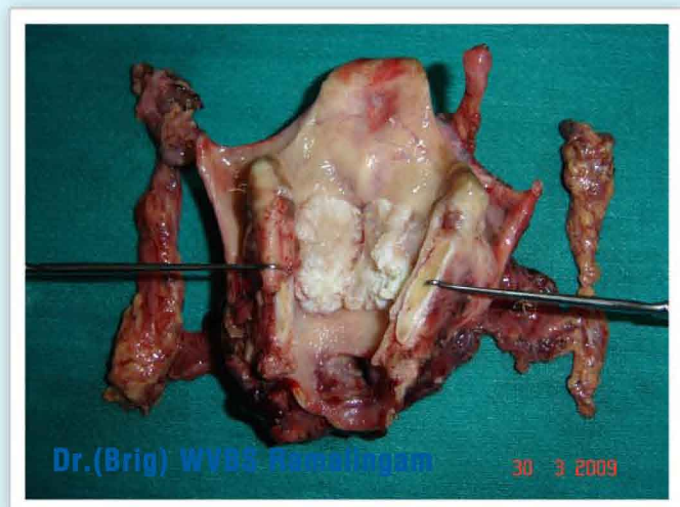
Closure of wound after creating neo pharynx or food pipe



Dr.(Brig) WVBS Ramalingam

30 3 2009

Post operative appearance after Total laryngectomy



Dr.(Brig) WVBS Ramalingam

30 3 2009

Specimen of Larynx showing tumour of larynx